



maxgraft[®] cortico

Prefabricated allogenic bone plate

Surgical guide

hard tissue

innovative

efficient

atraumatic

Content maxgraft® cortico

Surgical guide

1. Introduction	p3
2. Indications	p4
2.1 Indications for maxgraft® cortico	
2.2 Product properties	
2.3 Use of maxgraft® cortico in conjunction with other biomaterials	
3. Surgical procedure	p5
3.1 Pre-operative assessment and treatment planning	
3.2 Shell technique with maxgraft® cortico	
3.2.1 Basic information/requirements	
3.2.2 Step-by-step procedure	
3.2.3 Suturing technique	
4. Post-operative care	p7
5. Healing	p8
5.1 Remodeling and new bone formation	
5.2 Re-entry	
5.3 Implant placement	
6. Further information	p9
6.1 Advantages of maxgraft® cortico	
6.2 maxgraft® cortico vs. autogenous bone	
6.3 Stability vs. vitality	
6.4 Learning curve of the surgical procedure	
6.5 Safety	
7. Complication management	p10
8. Cases	p11
9. Important guidelines / FAQ	p14
10. Specifications	p15

1. Introduction

maxgraft® cortico is a prefabricated cortical bone plate from post-mortem human donor bone, that can be used for the shell technique. The concept of the shell technique is the preparation of a biological container, which creates the necessary space for the full incorporation of particulated bone graft material to rebuild new bone for dental implant placement, also published as cortical lamina technique¹ or framework technique².

maxgraft® cortico was developed to avoid the donor-site morbidity and to prevent the time-consuming harvesting and splitting of autogenous intra-oral bone blocks. It functions as non-native, avital cortical plate that is firmly integrated for optimal stabilization of the particulated augmentation material.

1. Deepika-Pennemetsa, S., Thomas, R., Baron, T., Shah, R., & Mehta, D. (2016). Cortical lamina technique: A therapeutic approach for lateral ridge augmentation using guided bone regeneration. *Journal of Clinical and Experimental Dentistry*, 9(1), 0–0.
2. Wallowy, P., & Dorow, A. (2012). Lateral Augmentation of the Maxilla and Mandible Using Framework Technique With Allogeneic Bone Grafts. *The Journal of Oral Implantology*, 38(6), 661–667.

2. Indications and general information

2.1 Indications for maxgraft® cortico

Implantology — Oral Surgery — CMF Surgery

- Vertical augmentation
- Horizontal augmentation
- Complex three-dimensional augmentations
- Single tooth gaps
- Fenestration defects

Highest success rates can be achieved for defects with a maximum size of 6 mm horizontally or vertically. maxgraft® cortico can be used for both upper and lower jaw. Application in the posterior mandible is facilitated due to the possibility of an additional lingual flap mobilization.

2.2 Product properties

- Acellular cortical bone from the femur diaphysis (multi-organ-donors, post-mortem)
- Osteoconductive properties supporting natural and controlled tissue remodeling
- Fully mineralized for natural stability, no flexibility
- Reliable thickness of < 1 mm
- Standardized size 25x10 mm
- 5 years shelf life at room temperature
- Safe and sterile

2.3 Use of maxgraft® cortico in conjunction with other biomaterials

maxgraft® cortico is intended to be used in conjunction with additional biomaterials. A variety of different bone grafting materials are available. Allogenic material (maxgraft® granules) with its preserved human collagen provides excellent osteoconductive properties and enables complete remodeling and thus is the recommended choice. Mixing with autogenous chips and Emdogain® can support a faster ossification. Also other mixtures of different materials (e.g. bovine or synthetic biomaterials) can be used to fill the containment. Generally we recommend to use a mixture of allogenic and autogenous bone. The final decision depends on the defect morphology and preferences of the patient and surgeon.

3. Surgical procedure

3.1 Pre-operative assessment and treatment planning

Careful patient selection is critical for the outcome of the surgical procedure and the long-term success of the treatment. Proper case selection requires thorough review of the patient's medical and dental history, the anatomy and the residual bone height as well as bone quality by clinical and radiographic examination. Special attention should be paid to patient-related factors that may affect bone healing. General contraindications are considered to be the same as for GBR, such as but not limited to an acute inflammation and poor oral hygiene. A pre-operative antibiotic treatment may be considered. Further site-specific assessment should include treatment planning for the ideal implant type, diameter, length, number and position. These parameters help to determine the appropriate volume of new bone that has to be created.

3.2 Shell technique with maxgraft® cortico

3.2.1 Basic information/requirements

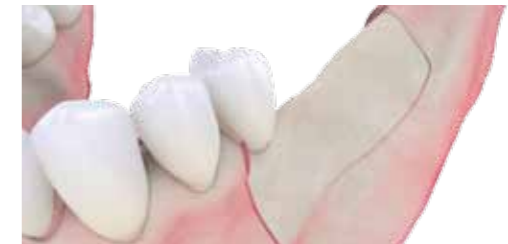Depending on the scope of the procedure and patient profile the cortico-procedure is performed under local or general anesthesia. For a successful procedure, please follow the following recommendations:

- During treatment planning, carefully assess the soft tissue situation.
- A passive and careful flap preparation and tension-free wound closure is critical for the success of the shell technique.
- The temporary restoration following augmentation must not exert any mechanical pressure on the graft.

3.2.2 Step-by-step procedure

Step 1 — Flap Preparation

A flap large enough to allow full access to the entire defect should be raised. Also an adequate revascularization of the particulated bone graft material is crucial and needs to be ensured. The required size and position of the bone plate can be determined either during digital planning of the operation or following flap elevation *in situ*.



Note: For best success rates it is recommended to limit the augmentation to 6 mm horizontally or vertically.

Step 2 — Trimming

By using the botiss cortico trimmer and a rotating diamond disc maxgraft® cortico is cut to the appropriate size extraorally. The botiss cortico trimmer also facilitates the preparation of the pilot holes for the later fixation of cortico to the local bone. By predrilling the fixation holes the risk of fracturing maxgraft® cortico can be reduced.

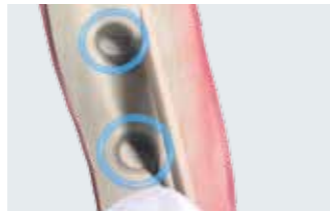


Note: Hydration of the bone plate is not needed. During the surgery, maxgraft® cortico can be placed into saline or antibiotic solution.

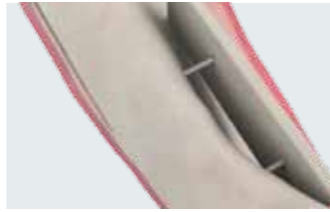

Step 3 — Placement and fixation

To create a fixed compartment maxgraft® cortico must be positioned in adequate distance to the local bone. Based on the ideal implant position, the plate should be positioned with at least 1 mm distance to the implant surface when placed laterally. Tension free fixation without bending of the plate is highly important.



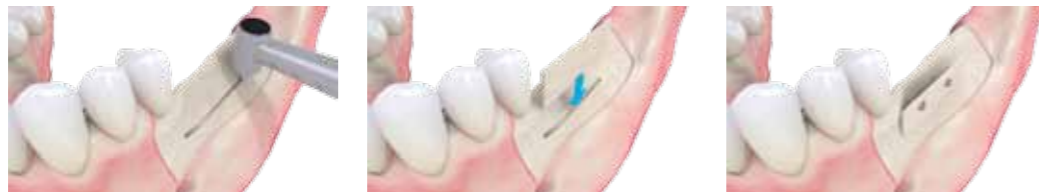Note - screws: Usually 2 screws are sufficient to rotation free fixate cortico to the patients' bone. It is crucial that the fixation of maxgraft® cortico ensures complete immobility of the bone plate. Screws consisting of surgical steel with a diameter of 1.0 mm, or titanium with 1.2 – 1.4 mm and a length of 8 -11 mm are appropriate for most defects. Use of flat-headed osteosynthesis screws and a predrilling of fixation holes is strongly recommended.



- Self-tapping screws should be avoided as they may result in fracture of the plate due to the aggressive thread design.
- Sinking the screw head into the bone plate should be avoided, as this might result in a loss of stability.

Note – lateral distance: The maximal lateral distance is limited by sufficient stabilization of the plate and adequate soft tissue coverage of the bone plate.

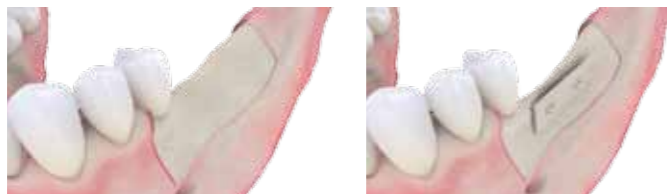
Optional- groove technique



Advanced surgeons may use the groove technique for improved primary stability of the plate. An approximately 1 mm wide and straight groove is cut in the local bone using piezoelectrical or rotating instruments, in which maxgraft® cortico can be positioned before fixation.

Step 4 — Adaptation of the edges

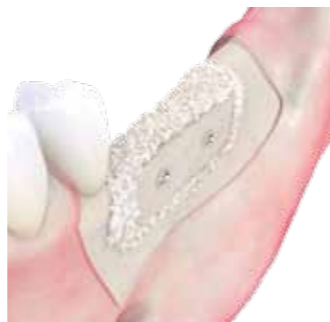To prevent perforations of the soft tissue, **sharp edges need to be removed explicitly**, e.g. by using a diamond ball mill.



Step 5 — Filling of the defect

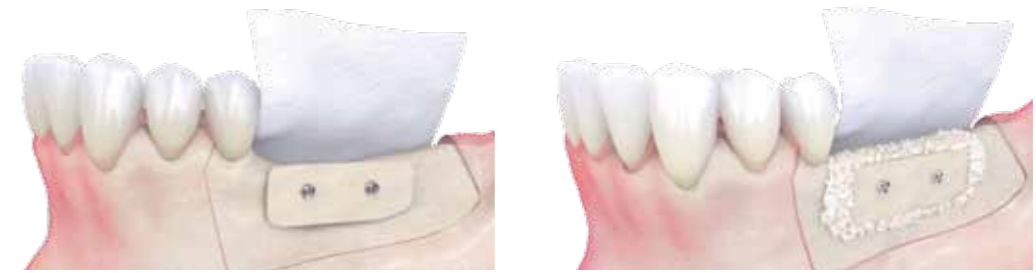The space between local bone and cortical plate shall be filled with particulated bone grafting materials. The use of autogenous and allogenic materials is recommended.

Note: The excellent osteoconductive properties of allogenic granules (maxgraft® granules) enables a fast regeneration of vital bone and a complete remodeling. Thus they are the primary recommended particles. Mixing with autogenous bone chips can support and speed up the initial ossification. The use Emdogain® may support woundhealing.



Step 6 — Coverage by a barrier membrane

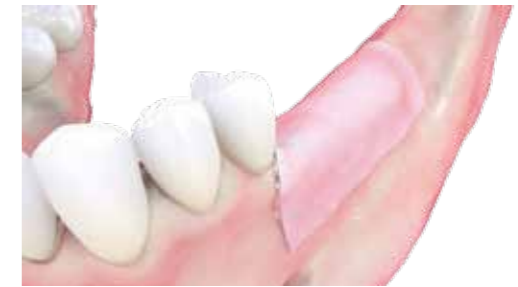The augmentation area needs to be covered with a long lasting barrier membrane (e.g. Jason® membrane).



Note: Membrane coverage of the augmented site is mandatory. The barrier membrane prevents the in-growth of soft tissue into the particulate material.

Step 7 — Wound closure

The suture has to be absolutely tension free and saliva proof.



Note: Proper soft tissue management is crucial for the surgical success. A tension free wound closure and a sufficient quality of the soft tissue significantly reduces the risk of complications such as dehiscences.

Tenting technique

Especially for vertical defects maxgraft® cortico can be placed horizontally to tent off the soft tissue. By adapting the width of the plate, the crestal dimensions can be adjusted to finally fit the desired type of implant. By using rotating instruments or piezoelectrical devices, the contact points of the plate to the local bone can be flattened for optimal immobilization. A safety distance of approximately 1 mm to the neighboring teeth should be maintained. After fixation of the plate, the particles can be placed from the buccal aspect and the whole area can be covered with a barrier membrane to immobilize the particles. Additional lateral application of further plates are not considered necessary.

3.2.3 Suturing technique

Single knot or continuous (or continuous interlocking sutures) should be used for primary closure. Deep apical back-action sutures using Gore-Tex® for elasticity can be used for immobilization of the flaps, thus eliminating any tension on wound edges, which may lead to dehiscence.

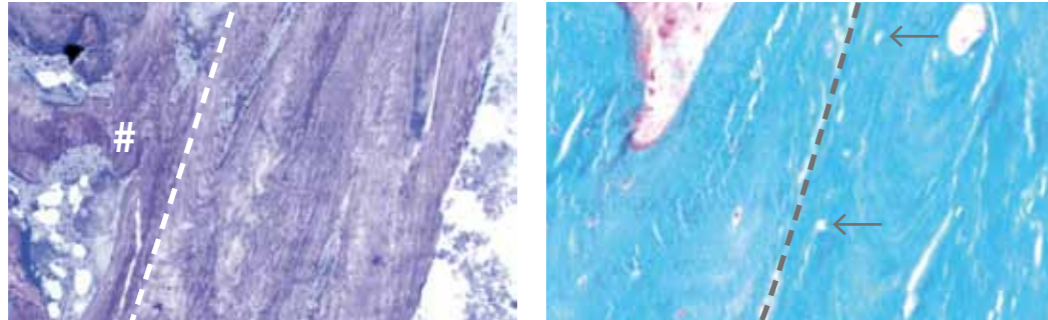
4. Post-operative care

1. The patient should be instructed not to mechanically irritate the surgical site, e.g. by tooth brushing or chewing hard food and to report any suspicious events such as soft tissue perforations and wound dehiscence immediately. A post-operative CBCT or X-ray should be considered.
2. Remove sutures about 10 days after surgery.
3. Arrange further review visits to control early wound healing.

5. Healing

5.1 Remodeling and new bone formation

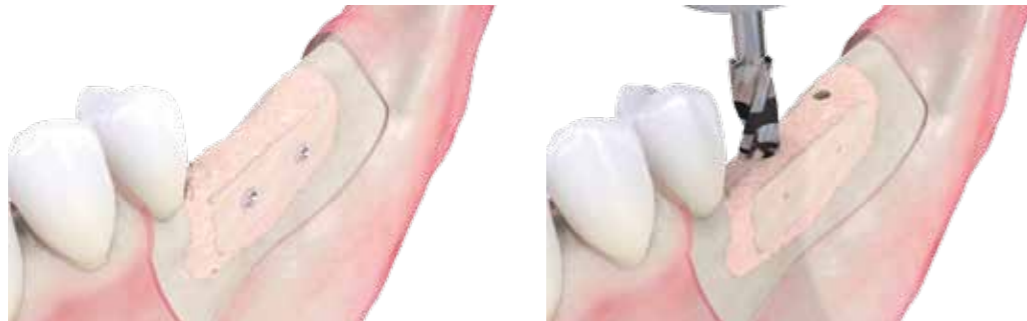Postoperatively, maxgraft® cortico usually gets primarily integrated within 6 months. Since the bone plate consists of cortical bone it is not resorbed quickly, but will be secondarily remodeled. Resorption mainly takes place in areas that are located outside the contour. New vital bone is formed directly adjacent to the allogenic plate at the side facing the local bone. When compared to autogenous grafts cortico shows an enduring stability.



Depicted is a histological examination of an integrated cortico plate (right) stabilizing allogenic particles (#) after 5 months of healing. maxgraft® is characterized by empty osteocyte lacunae (arrows), whereas the newly generated bone lines basically. Every allograft surface shows a large number of vital osteocytes. Biopsy provided by Jan Kielhorn (Öhringen, Germany) processed by Prof. Smeets (UKE Hamburg, Germany)

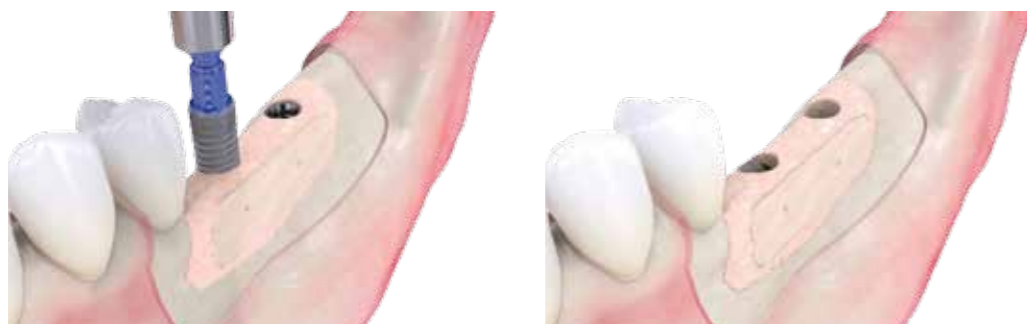5.2 Re-entry

Depending on the location, type and extent of the defect, the entire healing time is 4 to 6 months when using allogenic particles and autogenous bone. However, the right time for the re-entry needs to be estimated individually by the surgeon.



5.3 Implant placement

The implant has to be anchored securely in the cancellous bone and should not have any contact with the plate. A minimum of 1 mm cancellous bone surrounding the implant is recommended in order to ensure a sufficient long-term function in vital bone tissue.



6. Further information

6.1 Advantages of maxgraft® cortico

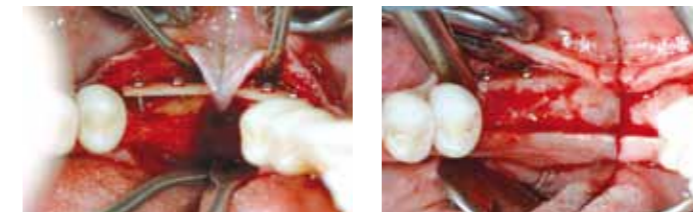- Natural and fully biocompatible barrier
- Volume stable due to full mineralization
- Universal application, whenever a bony wall is missing
- Standardized size of 25 x 10 mm
- Reliable thickness of < 1 mm
- Less invasive than autogenous techniques
- Unlimited availability compared to autogenous bone grafts

6.2 maxgraft® cortico vs. autogenous bone

Compared to autogenous bone harvested from the iliac crest or intraoral sites, maxgraft® cortico provides a prolonged barrier.

6.3 Stability vs. vitality

The volume stability is provided by maxgraft® cortico itself, the particulated grafting material ensures rapid formation of new vital bone.

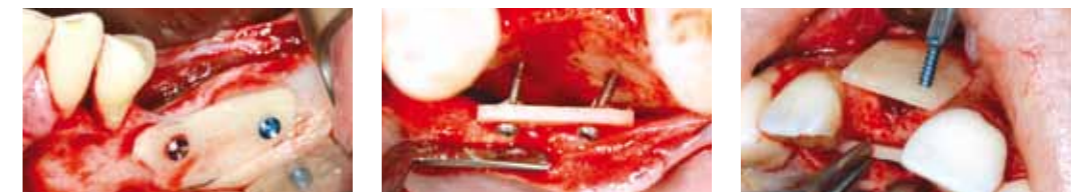

Pictures kindly provided by
Dr. Christoph Keller, Stuttgart, Germany

6.4 Learning curve of the surgical procedure


Just like in every other surgical procedure, performing the shell technique with maxgraft® cortico underlies a learning curve. Prior to the first-time application courses like lectures or hands-on workshops should be attended. Preferably the surgeon has experience in harvesting autogenous bone grafts. Furthermore, a supervision by an experienced surgeon can be recommend to check the indication of the specific case. Advanced surgeons can apply the groove technique for placing the bone plate in the lateral lower or upper jaw.

The easiest indication is a lateral augmentation with contact of the plate to the local bone. The difficulty is increased when the contact to the local bone is diminished or when a second plate is fixed on the opposite site of the ridge.



6.5 Safety

maxgraft® cortico is acellular and resistant to bacterial degradation even when exposed.



Dense cortical bone structure of maxgraft® cortico (Institute Straumann AG, Basel, Switzerland)

7. Complication management

Postoperative treatment

The general principles of implant insertion always have to be respected.

If the initially desired height of the bone cannot be achieved by the augmentation there is the risk of placing the implant "too deep". In this case re-augmentation with granules is highly recommended.

Fracture of the plate

maxgraft® cortico is a highly stable bone plate. It has to be fixated free of any movement without excessive pressure or tension. In the unlikely case of a fracture it must be fixated with an additional screw or replaced by a new bone plate. The use of the cortico trimmer (Cat.No. BO-34000) reduces the chance of fracture during cutting and extraoral drilling and is ideal for precise adaptation. (Animation available)

Wound dehiscence

In absence of any kind of signs of infections rinsing with Rivanol/ H₂O₂ once a week for approximately 4 - 6 weeks.

Smoothing sharp edges or reducing free standing parts of plate below tissue level if possible.

Filling dehiscence gap with Socketol or if too shallow with Solcoceryl may be beneficial.

Continue treatment until secondary wound closure is complete or if healthy tissue conditions are achieved.

Soft tissue perforations

Late soft tissue perforations after normal wound healing:

In absence of any signs of infection reduce sharp edges or remove free standing parts of the plate. maxgraft® cortico does not have to be removed completely. Free parts of the plate may be covered using Solcoceryl.

In case of irritations of surrounding soft tissue, use rinsing protocol as described above.

Soft tissue management may be performed earliest after 6 weeks if necessary.

Loosening of the plate at the time of re-entry

If the plate should not be connected to the bony site in rare cases, it should be removed.

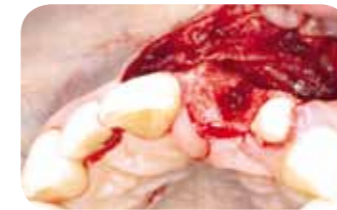The allograft bone augmentation below may be covered with a thin tissue which can be removed or left in place.

The augmentation site is usually fully regenerated.

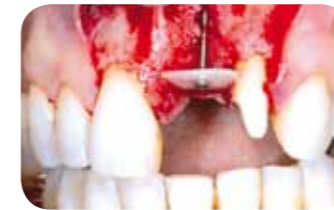8. Cases

Single tooth restoration with maxgraft® cortico

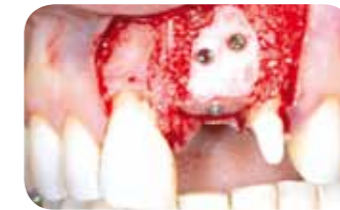Clinical case Dr. Krzysztof Chmielewski, Gdansk, Poland



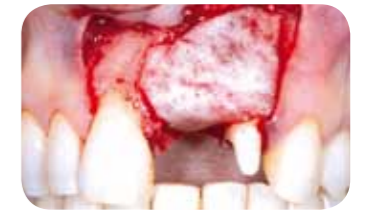Single tooth defect with severely resorbed vestibular wall



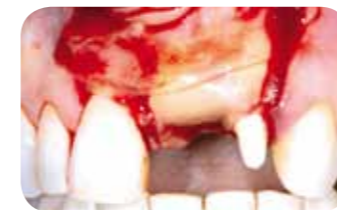Fixation of maxgraft® cortico using an osteosynthesis screw



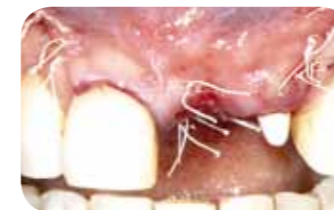Augmentation with maxgraft® granules mixed with particulated PRF matrices and fixation of a second maxgraft® cortico



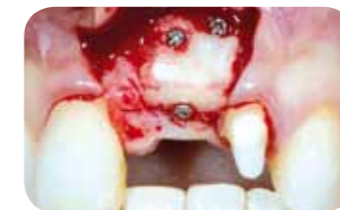Covering of the augmentation area with Jason® membrane



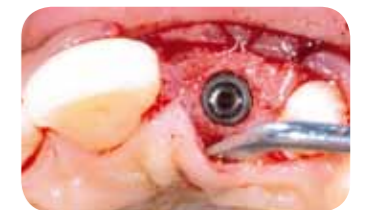Covering with a PRF matrix for improved soft tissue healing



Tension-free wound closure

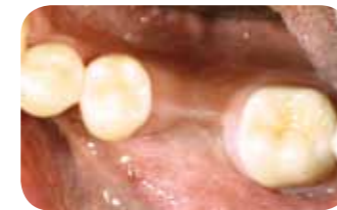

Situation after a healing period of four and a half months

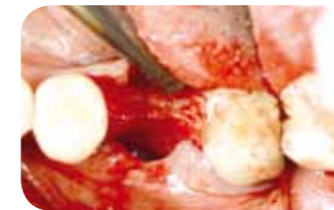

Stable implantation

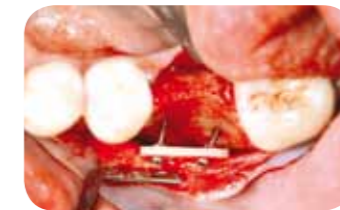Clinical case Dr. Christoph Keller, Stuttgart, Germany



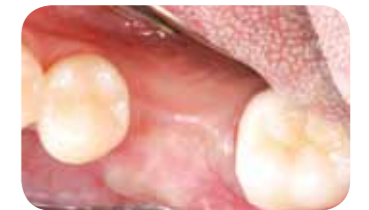Narrow ridge in the molar region



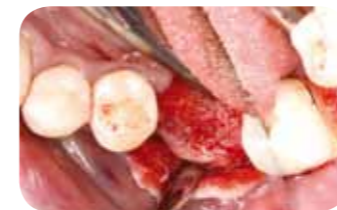Large buccal bone deficit



Stable fixation of cortico, note the non-parallel angulation of the screws for improved immobilization



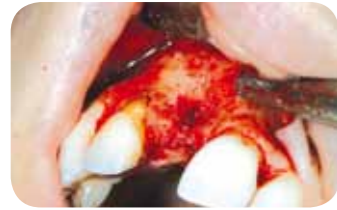Defect was filled with cancellous allograft particles and covered with a collagen membrane. Depicted is the healing after 4 months



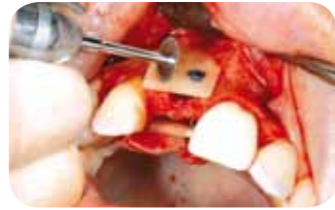Solid bone formation

Combined defect palatally and facially

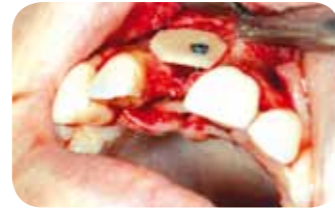Clinical case Dr. Kai Höckl, Freiburg, Germany



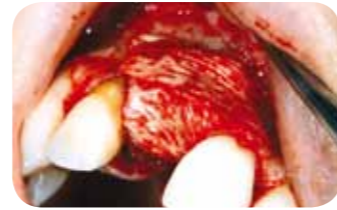
Clinical situation pre-operative



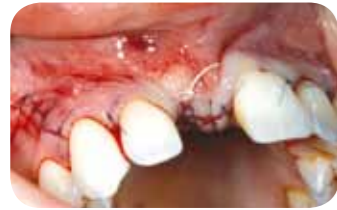Fixation of cortico facially and palatally



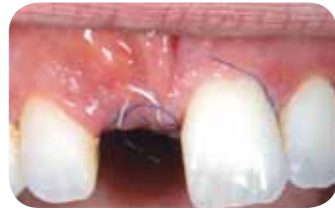Removal of sharp edges



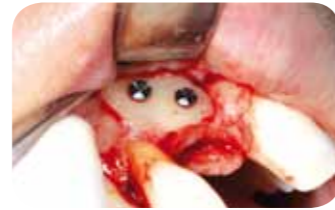Filling of the defect with autogenous chips and covering with Jason® membrane



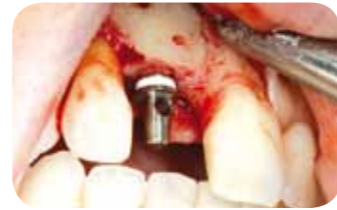Clinical situation post-operative



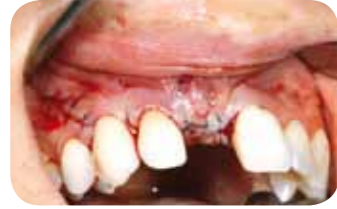Healing after 10 days



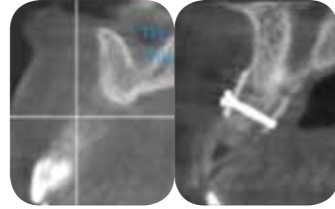
Re-entry after 5 months



Solid integration of cortico and implant placement



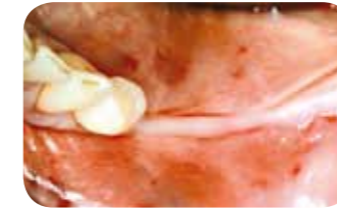
Wound closure



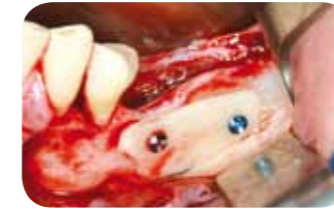CBCT pre- and post-op

Free-end situation in the mandible

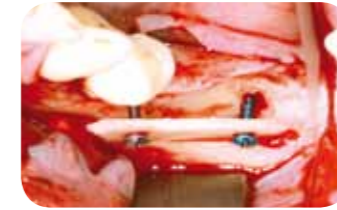
Clinical case Jan Kielhorn, Öhringen, Germany



Clinical situation



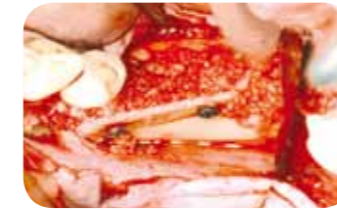Fixation of cortico, taking into account the bone level of the next tooth and thorough removal of sharp edges



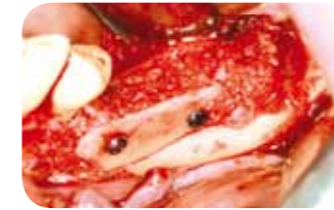Adequate distance to the local bone, angulated positioning of the screws and application of the groove technique



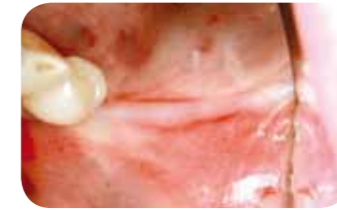Mix of allograft and autogenous chips



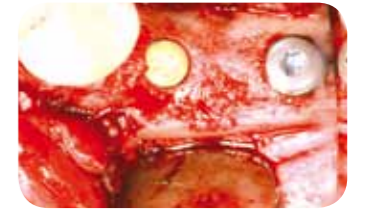
Filling of the defect



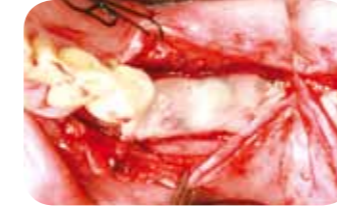Contouring with particles also outside of cortico to prevent perforations



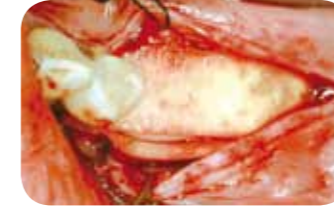Uneventful soft tissue healing



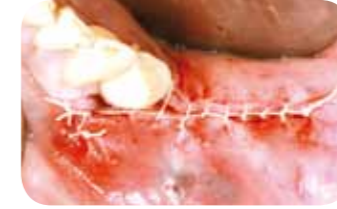Implant insertion 8 months after augmentation



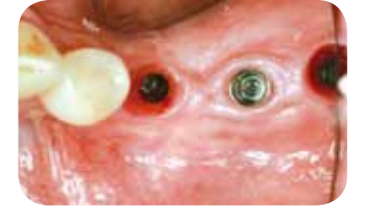Covering with PRF matrix



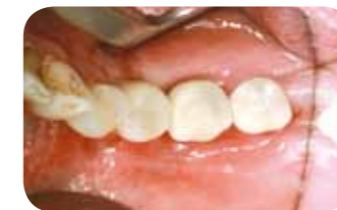Soft tissue improvement with mucoderm® crestally and laterally



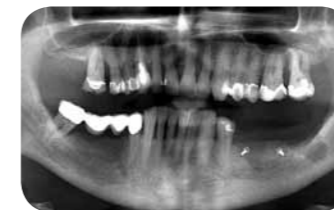Tension free wound closure



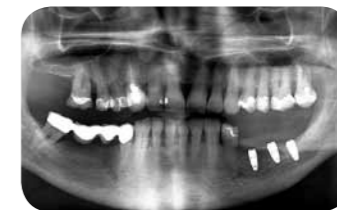Emergence profile prior to installation of provisionals



Provisional restoration in place



OPG post-augmentation



OPG post-implantation

9. Important guidelines / FAQ

Q: In which situation should the plate be removed?

A: Only if the plate is mobile.

Q: What is the recommended time until implant placement?

A: This depends on the chosen grafting material and the defect size. Usually 4 - 6 months produce sufficient new bone for dental implant placement.

Q: Can maxgraft® cortico be bend to follow the ridge contour?

A: No, maxgraft® cortico is fully mineralized and not flexible at all. For the incisor region, the plate can be cut in the middle and fixed as two parts.

Q: Can remaining fragments be resterilized?

A: Each plate must be used for a single patient only to guarantee sterility. Sterilization will destroy the structure, rendering the fragment ineffective.

Q: Is it mandatory to use a collagen membrane, as there are no membranes used with autogenous shell technique?

A: In terms of guided bone regeneration a membrane is mandatory.

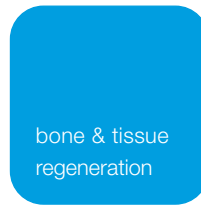10. Specifications

31251	maxgraft® cortico	25 x 10 x 1 mm	1 piece
31253	maxgraft® cortico	25 x 10 x 1 mm	3 pieces



34000 cortico trimmer





Innovation.
Regeneration.
Aesthetics.

soft tissue

education

hard tissue

botiss biomaterials GmbH
Hauptstr. 28
15806 Zossen
Germany

Tel.: +49 33769 / 88 41 985
Fax: +49 33769 / 88 41 986

www.botiss.com
www.botiss-dental.com
facebook: botissdental